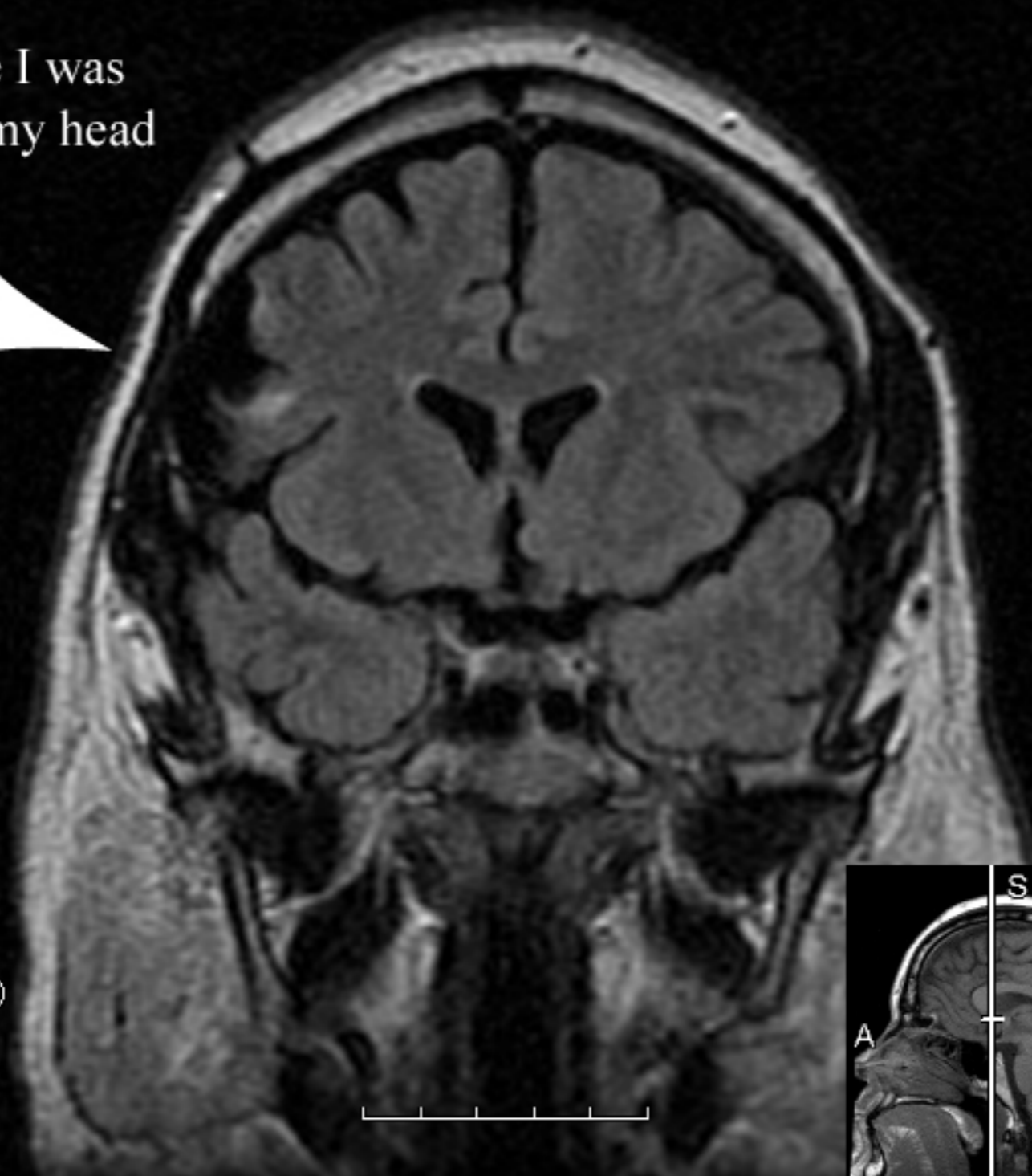


Ser: 6/Img: 9
Loc: 24.8 mm
357 /715

S
HFS

Bonner General Hospital MRI
SWENSON, MICHAEL
122671
4/14/06 17:55:54

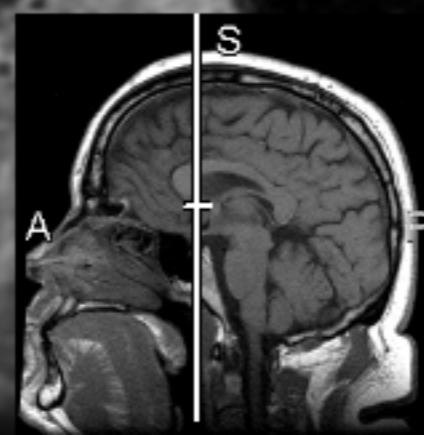
This image shows where I was
shot in the right side of my head



R

L

256 x 192/0.5 NEX
TR 8002/TE 127/TI 2000/Flip Angle 90
Thk 5 mm/FOV 24 cm
18:14:48
9/25 COR FLAIR TR=8002 TE=127.5



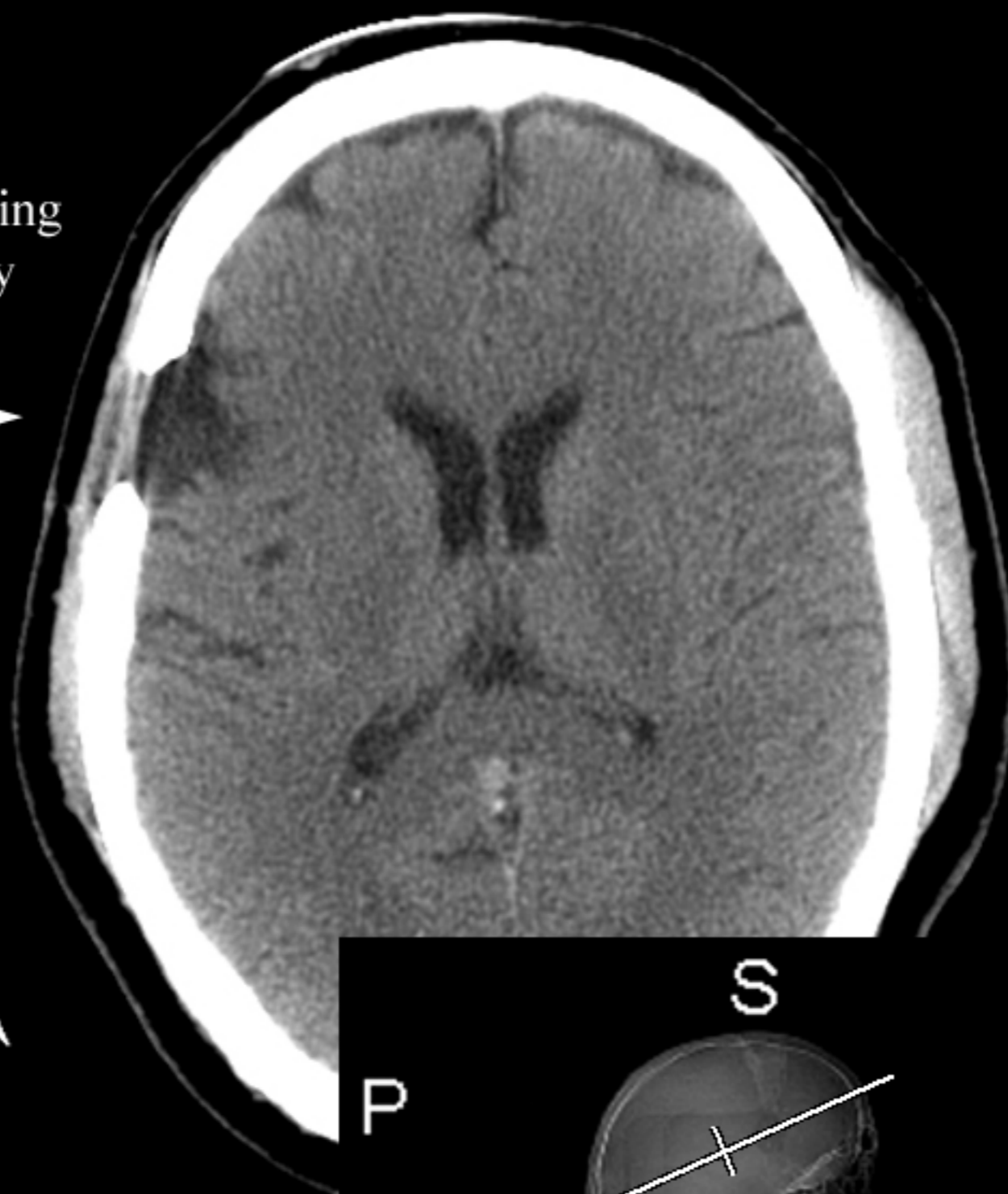

2.5x

Ser: 2/Img: 13
Loc: 31.3 mm
40 /100

A
HFS

Bonner General Hospital
SWENSON, MICHAEL E.
122671
9/28/04 13:22:05

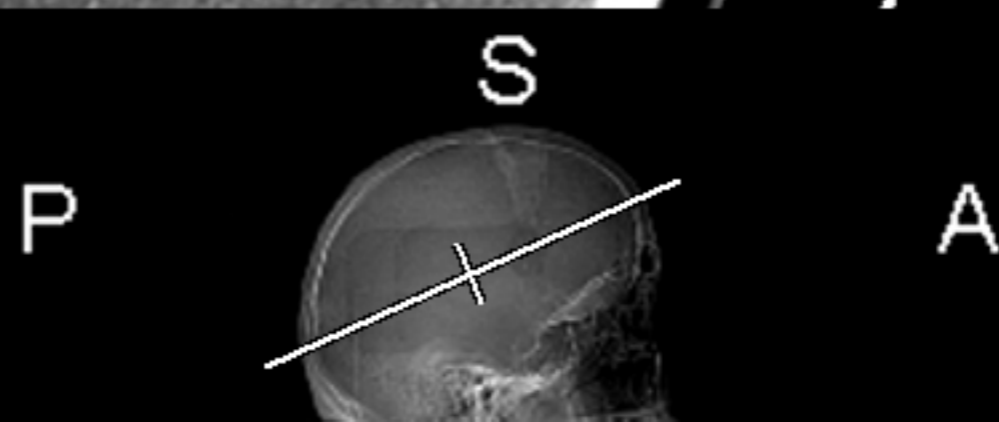
Another image showing
1988 Head Wound by
Gun shot



R

L

kV 140/mA 256
Tilt: 22
Thk 5 mm/FOV 23 cm
13:24:51
13/29 S 2



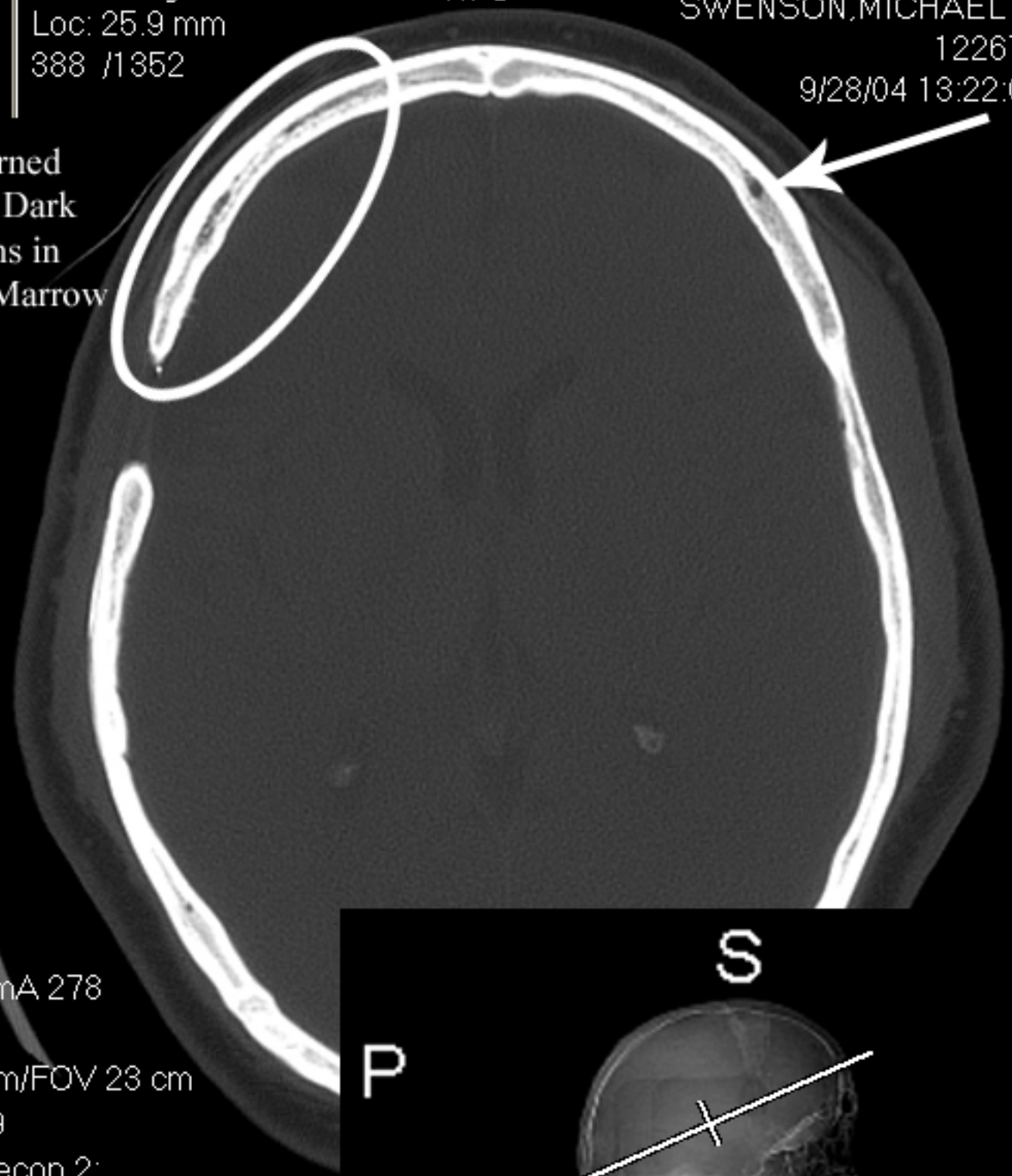
1.2x

Ser: 3/Img: 12
Loc: 25.9 mm
388 /1352

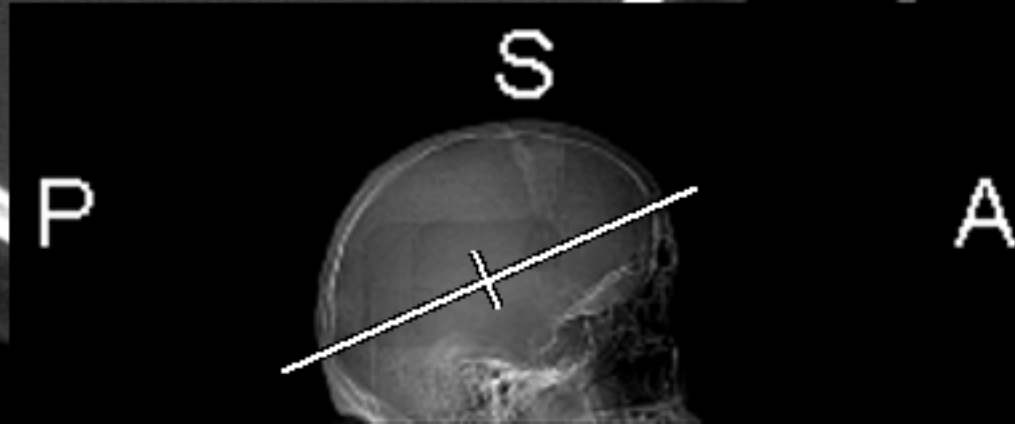
A
HFS

Bonner General Hospital
SWENSON, MICHAEL E.
122671
9/28/04 13:22:05

Concerned
About Dark
Regions in
Bone Marrow



kV 140/mA 278
Tilt: 22
Thk 5 mm/FOV 23 cm
13:28:19
12/31 Recon 2:



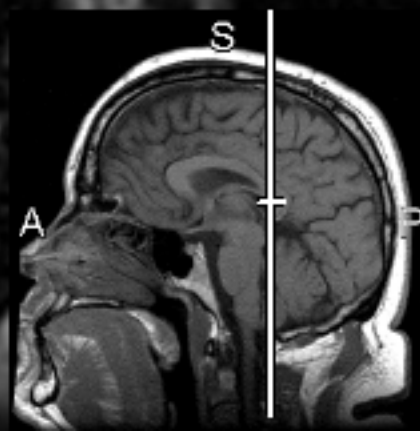
Ser: 6/Img: 16
Loc: -20.2 mm
304 /608

S
HFS

Bonner General Hospital MRI
SWENSON, MICHAEL
122671
4/14/06 17:55:54



256 x 192/0.5 NEX
TR 8002/TE 127/TI 2000/Flip Angle 90
Thk 5 mm/FOV 24 cm
18:14:48
16/25 COR FLAIR TR=8002 TE=127.5



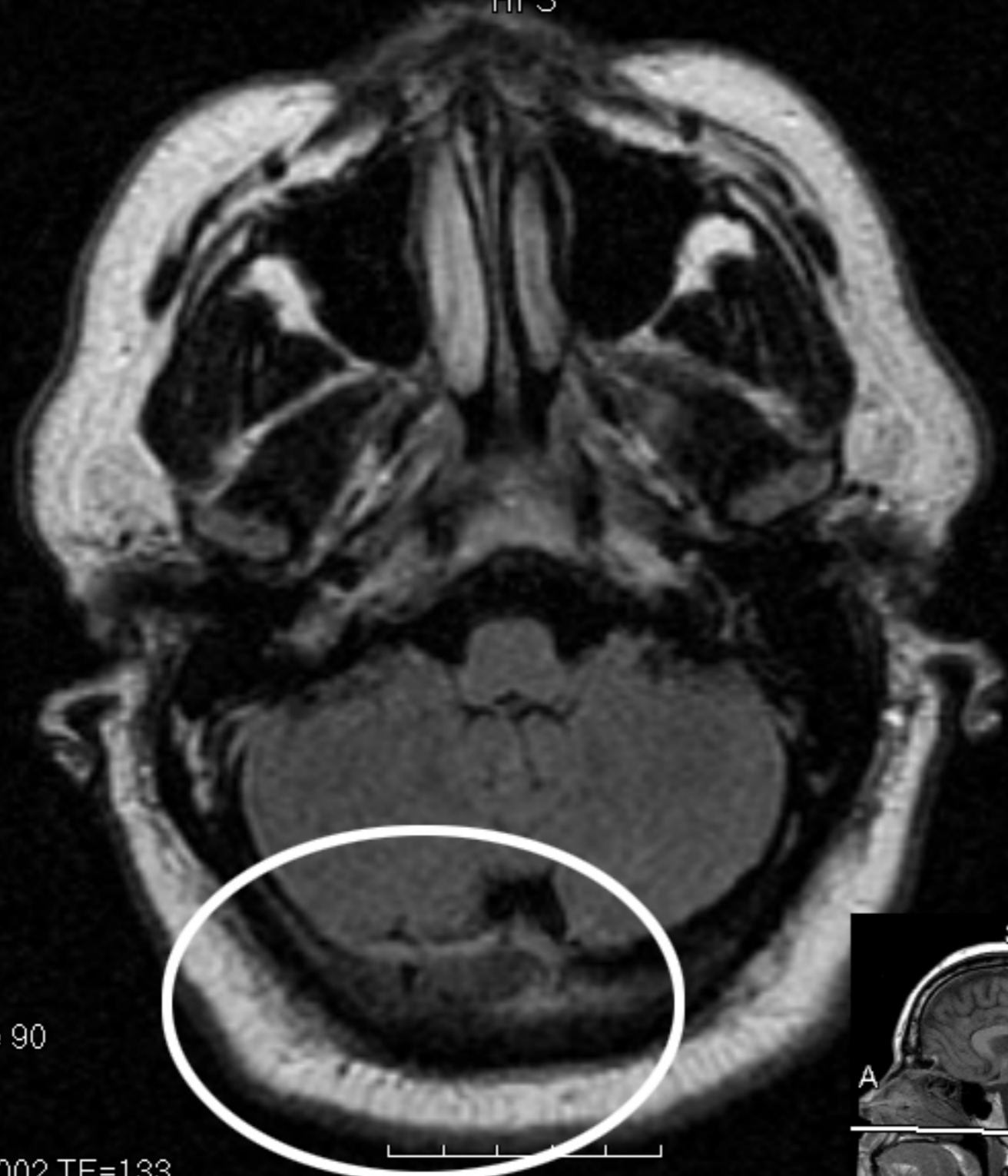Ser: 3/Img: 5
Loc: -85.3 mm
307 /615

A
HFS

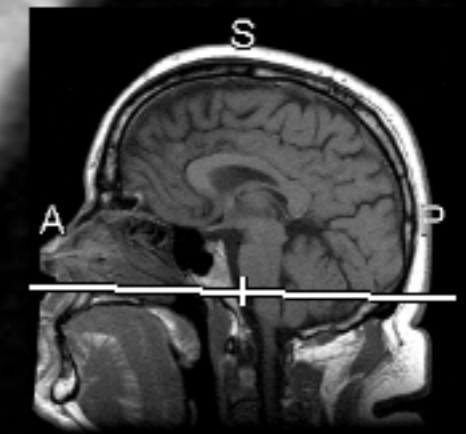
Bonner General Hospital MRI
SWENSON, MICHAEL
122671
4/14/06 17:55:54

R

L



256 x 192/0.5 NEX
TR 8002/TE 133/TI 2000/Flip Angle 90
Thk 5 mm/FOV 24 cm
18:01:19
5/23 AX FLAIR (NOT DR V) TR=8002 TE=133



2.5x